

A Diaphragmatic Rupture Due to Endometriosis and Iatrogenic Origin

Randrianambinina Fanomezantsoa^{1, 2, *}, Jonatana Arthur Daniel^{1, 2},
Le Pimpec Barthes Françoise¹, Rakotovao Hanitrana Jean Louis²

¹Department of Thoracic Surgery in AP-HP European Hospital Georges Pompidou, Decartes University, Paris, France

²Thoracic Surgery Department in Teaching Hospital Joseph Ravoahangy Andrianavalona (CHU-JRA), University of Antananarivo, Antananarivo, Madagascar

Email address:

fanomez_r@yahoo.fr (Randrianambinina Fanomezantsoa)

*Corresponding author

To cite this article:

Randrianambinina Fanomezantsoa, Jonatana Arthur Daniel, Le Pimpec Barthes Françoise, Rakotovao Hanitrana Jean Louis. A Diaphragmatic Rupture Due to Endometriosis and Iatrogenic Origin. *Journal of Gynecology and Obstetrics*. Vol. 10, No. 6, 2022, pp. 275-278.

doi: 10.11648/j.jgo.20221006.17

Received: November 21, 2022; Accepted: December 9, 2022; Published: December 29, 2022

Abstract: Introduction: A diaphragmatic rupture may have traumatic origin but may also have other causes such as endometriosis or iatrogenic origin. We report a rare case of right diaphragmatic rupture in a woman with thoracic and abdominal endometriosis that was treated surgically on the diaphragm. Observation: She was a 39-year-old woman diagnosed with thoracic and abdominal endometriosis in 2005 and had been performed with a talcage and stapling of an endometriosis nodule at the phrenic center by thoracoscopy and then operated twice with abdominal and gynecologic surgeries. She presented at the entrance of our service a bubble of emphysema, a chronic right pleural effusion and an image of a right diaphragmatic hernia with staples around the bank of the diaphragmatic perforation indicating a surgical re-intervention for diaphragmatic repair. She had, by a right lateral thoracotomy, a reparation of the diaphragmatic rupture with a non-resorbable prosthetic material. Conclusion: For diaphragmatic lesions or perforations, resection using the endoscopic stapler device is the most appropriate approach. Though, the diaphragm is weakened by endometriosis, and a small diathermic lesion or a small injury by the staples may enlarge. Even iatrogenic diaphragmatic hernias are rare, stapling should be avoided, and opt for resection or a manual diaphragmatic fold and suture by using of prosthetic materials.

Keywords: Diaphragm, Endometriosis, Hernia, Prosthetic Materials, Rupture

1. Introduction

The rupture of a diaphragmatic dome is most often post traumatic but other mechanisms may be involved. Thus an endometriosis, corresponding to an extra-uterine localization of endometrial mucosa may be the cause of such rupture as well as the surgical technique used in its treatment. Endometriosis within the lung parenchyma or on the diaphragm and pleural surfaces produces a range of clinical and radiological manifestations, including catamenial pneumothorax, catamenial hemothorax, catamenial hemoptysis, and pulmonary nodules. Collectively, this is known as thoracic endometriosis syndrome (TES) [1]. Recently, this classic definition of TES is expanding to

include endometriosis-related diaphragmatic hernia, catamenial chest pain, and endometriosis-related pleural effusion [2]. More than 80% of thoracic endometriosis is associated with abdominal localization [3]. For diaphragmatic lesions or perforations, resection using the endoscopic stapler device is the most appropriate approach [4]. In the literature, reports of recurrence are high [4]. We report a rare case of right diaphragmatic rupture in a woman with thoracic and abdominal endometriosis that was treated surgically on the diaphragm.

2. Observation

She was a 39-year-old, non-smoking woman with

endometriosis who was diagnosed in 2005 in Martinique by right pleural effusions. At the time, simple chest tube had been carried out and in 2013 it had benefited from a right thoracoscopy associated with a talcage and a stapling of a nodule of endometriosis on the phrenic center.

In November 2015, she had gynecological surgery in France, where she had performed a resection of uterine juxtaposed nodules and utero-sacral ligaments. Ascites reappeared following in vitro fertilization and then had been re-operated for removal of endometriosis nodules in the umbilicus and abdominal wall. Ascites remained and control imaging revealed a bubble of emphysema (figure 1), a right pleural effusion, and an image of a right diaphragmatic rupture with hernia of the upper part of the hepatic dome. On the periphery of this hernia existed a chain evoking a complete release of the stapling that had been initially performed (figure 2). Through the patient's symptomatology, such as recurrent septic pleural effusions, dyspnea and diaphragmatic rupture, the surgical intervention had been indicated. The respiratory functional balance showed a FEV1 at 79% of the theoretical value and a CV at 82%, a Tiffeneau ratio at 81% and a VR at 84%.

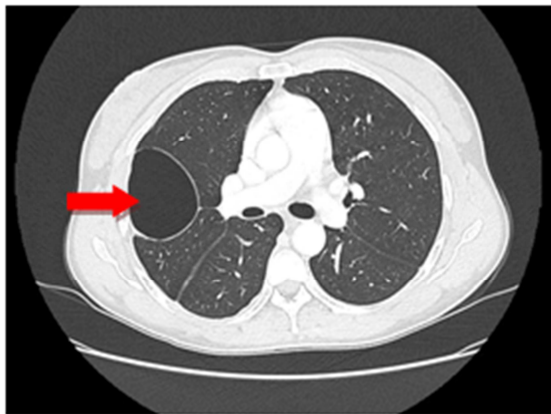


Figure 1. Scannographic image showing emphysema bubble.

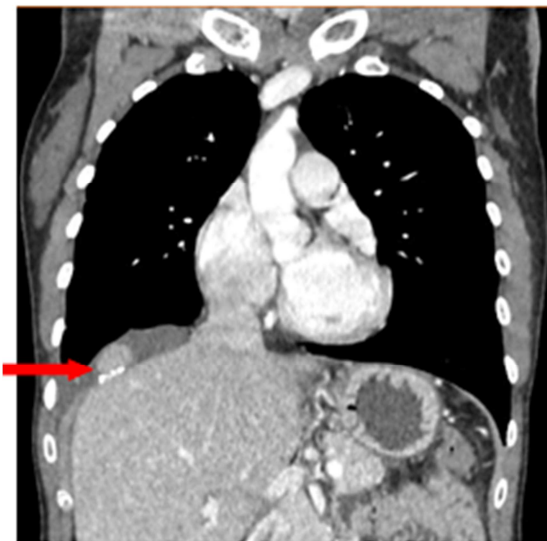


Figure 2. Scannographic image showing the hernia of a small part of the

liver with lines of staples on the bank of the diaphragmatic perforation.

By a short low right lateral thoracotomy, the exploration of the pleural cavity had revealed a pleural symphysis that was very heterogeneous leaving large free areas containing brown fluid and a diaphragmatic rupture sitting on the phrenic center with visualization of the top of the herniated liver through this rupture and staples on the periphery of this rupture. The surgery consisted of a pneumolysis, resection of the emphysema bubble, then liberation of the liver, section of the diaphragm at the periphery of the old rupture, and direct suture with placement of a non-resorbable prosthetic material, followed by the installation of anterior and posterior thoracic drains. The aftermath was simple.

3. Discussion

We had two hypotheses in the etiology of our patient's diaphragmatic rupture, which can be separated or associated, such as diaphragmatic endometriosis and post-operative iatrogenic complication of the diaphragm.

In the literature, several lesions may be suggestive of diaphragmatic endometriosis such as multiple (51%) or single (37%) "chocolate" nodules and cysts but are most widely described with perforations as the most observed anatomical lesion [2, 5, 6]. These lesions are essentially small in size, often millimeter (1-3mm), and rarely exceed 10mm. But large perforations (4 to 10mm) or complete diaphragmatic ruptures, like the one found in our patient, remain exceptional [7, 8].

Admittedly, the existence of multiple advances in medical treatment, the therapeutic association with surgery remains the gold standard in the treatment of endometriosis because the rate of recurrence is estimated 25 to 50% of cases after conservative treatment [9, 10]. The treatment of diaphragmatic lesions depends mainly on their infiltrating character, number and size [11]. Thoracoscopy remains the first most used route and the video-assisted mini-thoracotomy is only indicated for very extensive diaphragmatic lesions [12, 13]. Superficial diaphragmatic lesions can be treated with cold scissors, a monopolar or bipolar scalpel, a CO₂ or plasma laser [2]. Larger lesions or small punctures are better treated by resection and anastomosis either with an endoscopic stapler or by resection-suture [2, 14]. Resection with mechanical stapling allows on the one hand to make a histological sample and on the other hand to reduce the rate of recidivism. This procedure would also have the advantage of providing little post-operative diaphragmatic diseasement according to some studies, if the resection is less than 3 cm of diameter [14, 6].

However, in our case, the scannographic image of a hernia of the upper part of the hepatic dome with the existence of a chain on the periphery of this hernia evoked a diaphragmatic rupture secondary to the release of the staples. In the literature, iatrogenic diaphragmatic hernias are rare [15]. They are most often encountered after diaphragmatic surgery such as radiofrequency ablation of hepatocellular carcinoma,

laparoscopy for bile duct surgery, gastrectomy or gastric fundoplication in gastro-oesophageal reflux, pancreatectomy, or after nephrectomy [15, 16, 17]. But rarely after intrathoracic surgery as after esophageal surgery [18], after coronary artery bypass surgery [19], and there was one case reported after an upper pulmonary lobectomy by assisted videothoracoscopy [20]. This iatrogenic diaphragmatic hernia of our patient can then be explained by the existence of a small diaphragmatic diathermal lesion or a small mechanical tear of the diaphragm by a clamp or at the metal stapling points, which will expand over time due to pressure gradients between the pleural cavity and the abdominal cavity [15]. Thus, as the diaphragm is already weakened by endometriosis, Manual suture using X-stitches or an over lock suture with non-resorbable braided thread is better and most recommended to avoid secondary tearing, and prosthetic material may be necessary in case of a major defect [15]. In cases in which the lesions affect the full thickness of the diaphragm, the combined laparoscopy and thoracoscopy approach is useful in achieving complete resection of the diseased tissue [4]. Much of the recurrence (or persistence) of endometriosis is related to poor first surgery quality and to incomplete removal of all lesions [21]. Even the use of synthetic mesh has been recommended to close only larger diaphragmatic perforation in the literature [4], it helps to avoid recurrences and iatrogenic diaphragmatic hernia to all size of diaphragmatic defect because all lesions are removed, and the prosthetic material will strengthen the diaphragm.

4. Conclusion

Diaphragmatic and pleural disorders are the most common in thoracic endometriosis. Surgery is the main diagnostic and therapeutic means of this pathology. Since the diaphragm is very brittle by endometriosis, you should not use staples that are likely to injure the diaphragm but you should opt for a resection or a fold with a manual diaphragm suture. The use of prosthetic materials is the most indicated in the prevention and treatment of diaphragmatic ruptures.

Conflicts of Interest

The authors declare that they have no competing interests.

References

- [1] Joseph, Jos and Steven Sahn. "Thoracic endometriosis syndrome: new observations from an analysis of 110 cases". *Am J Med* 100 (1996): 164-9.
- [2] Bobbio, Antonio, Emeline Canny, Audrey Mansuet Lupo, Filippo Lococo, et al. "Thoracic endometriosis syndrome other than pneumothorax: clinical and pathological findings". *Ann Thorac Surg* 104 (2017): 1865-71.
- [3] Nezhat, Camran, Jillian Main, Chandhana Paka, and Azadeh Nezhat, et al. "Multidisciplinary Treatment for Thoracic and Abdominopelvic Endometriosis". *JSLs* 18.3 (2014): 1-7.
- [4] Nezhat, Camran, Steven R. Lindheim, Leah Backhus, Mailinh Vu, et al. "Thoracic Endometriosis Syndrome: A Review of Diagnosis and Management". *JSLs* 23.3 (2019): 1-8.
- [5] Legras, Antoine, Audrey Mansuet-Lupo, Christine Rousset-Jablonski, and Antonio Bobbio, et al. "Pneumothorax in women of child-bearing age: an update classification based on clinical and pathological findings". *Chest* 145.2 (2014): 354-60.
- [6] Alifano, Marco, Antoine Legras, Christine Rousset-Jablonski, and Antonio Bobbio, et al. "Pneumothorax recurrence after surgery in women: clinicopathologic characteristics and management". *Ann Thorac Surg* 92.1 (2011): 322-6.
- [7] Triponez, Frédéric, Marco Alifano, Antonio Bobbio, and Jean-François Regnard. "Endometriosis-related spontaneous diaphragmatic rupture". *Interact Cardiovasc Thorac Surg* 11.4 (2010): 485-7.
- [8] Bobbio, Antonio, Paolo Carbognani, Luca Ampollini, and Michele Rusca. "Diaphragmatic laceration, partial liver herniation and catamenial pneumothorax". *Asian Cardiovasc Thorac Ann* 15.3 (2007): 249-51.
- [9] Fagervold, Bente, Marita Jenssen, Lone Hummelshoj, and Mette Haase Moen. "Life after a diagnosis with endometriosis-a 15 years follow-up study". *Acta Obstetricia et Gynecologica Scandinavica* 8.88 (2009): 914-9.
- [10] Kim, Mi-La, Joo Myoung Kim, and Ju Seok Seong, et al. "Recurrence of ovarian endometrioma after second-line, conservative, laparoscopic cyst enucleation". *American Journal of Obstetrics and Gynecology*. 210.3 (2014): 1-216.
- [11] Wetzel. Mise au point sur la prise en charge chirurgicale de l'endométriose thoracique et diaphragmatique à partir d'une étude rétrospective multicentrique française. Médecine humaine et pathologie. 2018. dumas-01791478.
- [12] Tomasz, Marjański, Katarzyna Sowa, Aleksandra Czapla, and Witold Rzyman. "Catamenial pneumothorax – a review of the literature". *Kardiochirurgia i Torakochirurgia Polska* 13.2 (2016): 117-21.
- [13] Alifano, Marco. "Catamenial pneumothorax". *Curr Opin Pulm Med* 16 (2010): 381-6.
- [14] Alifano, Marco, Christine Jablonski, Habiba Kadiri, and Pierre Falcoz, et al. "Catamenial and noncatamenial, endometriosis-related or nonendometriosis-related pneumothorax referred for surgery". *Am J Respir Crit Care Med* 176.10 (2007): 1048-53.
- [15] Bini, Roberto, Diego Fontana, Alesandro Longo, and Paolo Manconi, et al. "Repair of diaphragmatic hernia following spinal surgery by laparoscopic mesh application: a case report and review of the literature". *World Journal of Emergency Surgery* 9 (2014): 34.
- [16] Abe, Tomoyuki, Hironobu Amano, Hitomi Takechi, and Nobuaki Fujikuni, et al. "Late-onset diaphragmatic hernia after percutaneous radiofrequency ablation of hepatocellular carcinoma: a case study". *Surgical Case Reports* 2 (2016): 25.
- [17] Suh, Younjin, Jun Hyun Lee, Haemyung Jeon, and Dongjin Kim, et al. "Late Onset Iatrogenic Diaphragmatic Hernia after Laparoscopy-Assisted Total Gastrectomy for Gastric Cancer". *J Gastric Cancer* 12.1 (2012): 49-52.

- [18] Khandelwal, Meena and Chad Krueger. "Diaphragmatic Hernia after Laparoscopic Esophagomyotomy for Esophageal Achalasia in Pregnancy". *ISRN Gastroenterology* (2011): 1-5.
- [19] Pathak, Digant, Om Tania, Tamonas Chaudhuri, and Jagat Pal Singh. "A Rare Variant of Diaphragmatic Hernia through the Central Tendon: A Case Report". *Indian J Surg* 76.3 (2014): 234-6.
- [20] Pan, Sai-Bo, Jian-Bin Zhang, Bai-Qin Zhao, and Ying Chai. "Delayed iatrogenic diaphragmatic hernia after thoracoscopic lobectomy". *J Thorac Dis* 8.6 (2016): E399-E402. doi: 10.21037/jtd.2016.04.14.
- [21] Rolla, Edgardo. "Endometriosis: advances and controversies in classification, pathogenesis, diagnosis, and treatment". *F1000 Faculty Rev* 8 (2019): 529.