

Spontaneous Bilateral Ectopic Tubal Pregnancy in Low-Resource Countries: About a Case in Burkina Faso, West Africa

Ouattara Adama^{1,*}, Lompo Dieudonné², Diallo Sadio³, Sawadogo Yobi Alexi¹, Kiemtoré Sibraogo¹, Ouédraogo Issa⁴, Ouédraogo Charlemagne Marie Ragna Newende¹

¹Department of Gynecology-Obstetrics, Joseph KI ZERBO University, Ouagadougou, Burkina Faso

²Department of Gynecology-Obstetrics, Regional Center of Gynecology-Obstetrics, Ziniaré, Burkina Faso

³Department of Gynecology-Obstetrics, Treichville University Hospital, Abidjan, Cote d'Ivoire

⁴Department of Gynecology-Obstetrics, Regional University Hospital, Ouahigouya, Burkina Faso

Email address:

ouattzangaadama@yahoo.fr (Ouattara Adama)

*Corresponding author

To cite this article:

Ouattara Adama, Lompo Dieudonné, Diallo Sadio, Sawadogo Yobi Alexi, Kiemtoré Sibraogo, Ouédraogo Issa, Ouédraogo Charlemagne Marie Ragna Newende. Spontaneous Bilateral Ectopic Tubal Pregnancy in Low-Resource Countries: About a Case in Burkina Faso, West Africa. *Journal of Gynecology and Obstetrics*. Vol. 11, No. 6, 2023, pp. 133-136. doi: 10.11648/j.jgo.20231106.11

Received: September 4, 2023; **Accepted:** November 6, 2023; **Published:** November 17, 2023

Abstract: *Background:* In developing countries, spontaneous bilateral tubal ectopic pregnancy is a very rare pathology. That form of extra-uterine pregnancy can lead to serious complication with high maternal morbidity and mortality if intervention is delayed. When diagnosed before the stage of complications, in particular tubal rupture, it essentially poses the problem of preserving subsequent fertility *Case:* the clinical case we present was documented in Burkina Faso, a country with limited resources in West Africa, at the gynecology obstetrics and reproductive medicine department of the Bogdogo university hospital. We are sharing the case of a 30-year-old para 1 gravida 2 patient who presented the signs of unbroken ectopic pregnancy. An ultrasound scan noted a left and right tubal ectopic pregnancy. At laparotomy, bilateral non ruptured tubal ectopic pregnancy was encountered. We decided to perform a left total salpingectomy with good hemostasis. The right ectopic pregnancy was treated with a salpingotomy with careful extraction of the conception product to maintain fertility. Our patient became pregnant 6 months after treatment. The situation was diagnosed in January 2022. *Conclusion:* bilateral ectopic pregnancy in a woman wishing to have children can be treated to preserve the patient's future fertility especially in developing countries where medically assisted reproduction is not yet available.

Keywords: Spontaneous, Bilateral Ectopic Pregnancy, Ouagadougou, Burkina Faso

1. Introduction

The incidence of ectopic pregnancy varies between 1.5-2% of all pregnancies. It is very often responsible for hemorrhagic complications making it a major cause of maternal mortality in African countries. More than 90% of them occur in the fallopian tubes. According to the majority of reports the frequency of ectopic pregnancy (EP) has grown in the last 30 years. Bilateral tubal ectopic pregnancy is rare and may occur in 1 per 200,000 pregnancies [1].

According to the literature, around 97% of extra-uterine

pregnancies occur in the fallopian tubes. Bilateral tubal ectopic pregnancy (BTP) is a very rare type of ectopic pregnancy. The early reported frequency of bilateral ectopic pregnancy has been estimated at 1/200,000 uterine pregnancies and 1/725-1/1580 ectopic pregnancies. The occurrence has tripled in the last decades with most cases being associated with assisted reproduction techniques (ART), use of intrauterine contraceptive devices (IUD), pelvic inflammatory disease (PID) and history of previous ectopic pregnancy or tubal surgery [2, 3].

Spontaneous ectopic pregnancies without risk factors or

ovulation induction are extremely rare with an estimated incidence of 1 in 725 to 1 in 1580 ectopic pregnancies [4]. The literature points to a correlation between these entities and the use of intrauterine devices and inflammatory pelvic diseases in recent decades [5, 6]. However, spontaneous cases do exist and are very rare. The ultrasound diagnosis is exceptional in preoperative diagnosis, it is most often intraoperative discovery. One factor to consider in this context is the appropriate surgery for fertility preservation. The potential risk of persistent trophoblasts and recurrence of ectopic pregnancy is supported by limited scientific studies. Despite this fact, salpingotomy is often preferred over salpingectomy to offer better fertility prospects [7]. We present a case of spontaneous bilateral ectopic pregnancy in the Gynaecology-Obstetrics and Reproductive Medicine Department of the University teaching Hospital of Bogodogo in Burkina Faso, west Africa, a developing country.

2. Case Presentation

She was a 30-year-old patient, culinary arts student, married, second gesture and primiparous with undocumented neonatal death, she is admitted to the Department of Gynaecology-Obstetrics and Reproductive Medicine for pelvic pain, which has been evolving for one week on a 2-month amenorrhea. She has in her possession an ultrasound scan performed on the same day suggesting an unbroken left EP. In this department, laparoscopy is not yet available due to a lack of resources. Ectopic pregnancies are managed by laparotomy, and medical treatment with cytotoxic drugs has not yet been adopted by doctors. The 2021-2022 report from the United Nations Development Program (UNDP) reveals that Burkina Faso was ranked 184th out of 191 countries.

Our patient does not remember the date of her last period. However, its cycle is well adjusted at 28 days. She has not received medically assisted reproduction or treatment for hypofertility and does not use any contraceptive method. She has no history of pelvic surgery.

The clinical examination at admission, our patient on 21/01/2022 at 12:30 pm notes: a good hemodynamic state with a blood pressure at 105/72mmHg and a pulse at 92 pulses per minute, anicteric colored conjunctiva. The breasts are even, symmetrical, anodular. The abdomen is flexible, depressible without organomegaly. The pelvis is soft and sensitive to palpation. The vulva is clean. The vaginal touch finds a short, centered and closed cervix. Vaginal touch combined with pelvic palpation reveals a uterus of gynecological size.

The plasma β -HCG measured on 21/01/2022 decreased to 169,943.50 mIU/ml.

The ultrasound that our patient was carrying with her suggests an unbroken left ectopic pregnancy. The one performed in our department finds an empty uterus with a thickened endometrium without a gestational sac. We noted the presence of a gestational sac of unbroken embryonic left latero uterine and a right adnexal mass of about 28mm. Douglass' dead end is free. After staff discussion, all clinical

and paraclinical findings would suggest a right ectopic pregnancy, a laparotomy is indicated. Intraoperatively, it was a bilateral ectopic pregnancy. Indeed, on the right we found a left ampullar ectopic pregnancy of about 4 cm with a large cracked embryonic axis and a right ampullar ectopic pregnancy of about 3 cm. In addition, a liquid cyst about 6 cm in diameter of the left ovary that underwent a cystectomy. The intraoperative view of the bilateral ectopic pregnancy is presented in Figure 1.

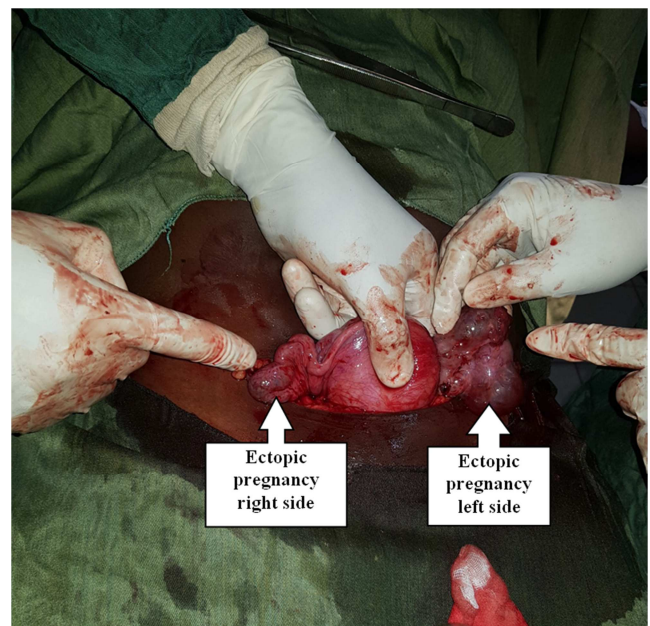


Figure 1. Operational view of the Bilateral ectopic pregnancy.

We first perform a left total salpingectomy with good hemostasis. The right ectopic pregnancy was treated with a salpingotomy with careful extraction of the conception product to maintain fertility. The anatomo-histo-pathological report of 30/01/2022 confirmed the diagnosis of bilateral ectopic pregnancy: histological aspect of bilateral GEU tubaires reworked by moderate inflammatory infiltration and serous cyst wall without malignancy within the limits of this sample. The post-operative course was uneventful. The treatment is completed by an injection of Methotrexate at a dose of 1 mg/kg body weight in the post-operative period. Plasma β -HCG control decreased to 147.50 mIU/mL within one week and to 4.50 mIU/mL after the second week.

3. Discussion

Preoperative diagnosis of spontaneous bilateral tubal ectopic pregnancy, a rare form of ectopic gestation, is difficult. Most patients with bilateral tubal ectopic pregnancy report the same symptoms as in unilateral ectopic pregnancy. It should also be recognized that the risk factors for these two conditions are virtually identical. Most authors agree that the most frequent symptoms are amenorrhea, vaginal bleeding and abdominal pain. The use of serum levels of the beta component of human chorionic gonadotropin (β -hCG) and the zone of discrimination are not reliable for patients with

bilateral disease [8, 9].

Spontaneous bilateral ectopic pregnancy is exceptionally rare. Its incidence is 1 in 200,000 intrauterine pregnancies and 1 in 725 to 1 in 1580 ectopic pregnancies [10]. Medically assisted reproduction is recognized as a major factor in the occurrence of ectopic pregnancy. Other factors such as pelvic inflammatory disease, the use of intrauterine devices, tubal surgery are associated with it. However, in half of the cases, no risk factors are found [11, 12]. This is probably the case for our patient in whom no risk factors are identified.

Numerous theories have been put forward to explain the occurrence of bilateral tubal pregnancies. Bilateral tubal gestation requires multiple ovulations, fertilization of the oocytes and their implantation at the sites of tubal lesions. Another possible etiology is transperitoneal migration of trophoblastic cells from one tube to the other, which explains the presence of fetal tissue in one tube and only villi in the other. Superfertilization is another possible etiology, with the fertilization and development of a second oocyte in a woman who is already pregnant. This is an extremely rare event, difficult to prove, and is suspected when a severe growth mismatch is observed in a multiple pregnancy. [13-15].

Bilateral ectopic pregnancy is difficult to diagnose. The diagnosis is rarely confirmed before surgery despite technological advances, particularly in ultrasound [16, 17]. This suggests rigorous training in pelvic ultrasound and the use of a good quality ultrasound machine and especially the systemization of the vaginal route for carrying out ultrasound in the first trimester of pregnancy.

There are no typical clinical and/or paraclinical signs of differential diagnosis between bilateral and single ectopic pregnancy. Indeed, the diagnosis of bilateral ectopic pregnancy cannot be formally made on the basis of serum β -HCG levels, serum progesterone levels or endovaginal ultrasound. It is necessary and useful to systematically check the adnexal against lateral to avoid misdiagnosis [18, 19]. In our case, the preoperative diagnosis was a left ectopic pregnancy and a fluid-like contralateral ovarian cyst. It was intraoperatively that we diagnosed bilateral ectopic pregnancy.

4. Conclusion

Although ectopic pregnancy is increasingly due to medically assisted reproduction, it is important to know that bilateral ectopic pregnancy is a very rare and potentially fatal entity that can occur in patients without any risk factors. Its preoperative diagnosis is difficult, hence the need for careful and systematic verification of the contralateral annex to avoid diagnostic errors. Laparoscopic surgery and open surgery are effective in treating ectopic pregnancies. However, further studies are needed to determine whether unilateral or bilateral conservative fertility preserving surgery is effective.

Conflict of Interest

The authors declare no conflict of interest.

Authors' Joint Input

OA and LP, the first two took care of the patient. the others contributed to the writing of the manuscript.

All the authors have read and agreed to the final version of the manuscript.

Special Thanks

Our sincere thanks go to all those who took part in our patient's care.

References

- [1] Jena SK, Singh S, Nayak M, Das L, Senapati S. Bilateral simultaneous tubal ectopic pregnancy: a case report, review of literature and a proposed management algorithm. *J Clin Diagn Res.* 2016 Mar; 10 (3): QD01-3.
- [2] Das S, Mahapatra B, Halder R, Talukder A. Spontaneous bilateral tubal pregnancy: a case report. *Journal of Dental and Medical Sciences.* 2015; 14 (12): 7-9.
- [3] Niviti S, Gokani KH. A rare case of spontaneous bilateral ruptured tubal ectopic pregnancy. *J Obstet Gynaecol India.* 2019; 69 (5): 470-472.
- [4] Andrews J, Farrell S. "Spontaneous bilateral tubal pregnancies: a case report," *Journal of Obstetrics and Gynaecology Canada*, vol. 30, no. 1, pp. 51–54, 2008.
- [5] Baron K. T, Babagbemi K. T, Arleo E. K, Asrani A. V, Troiano R. N. "Emergent complications of assisted reproduction: Expecting the unexpected," *Radio Graphics*, 2021; vol. 33, no. 1, pp. 229–244, 2013.
- [6] De Los Ríos J. F, Castaneda J. D, Miryam A. "Bilateral ectopic pregnancy," *Journal of Minimally Invasive Gynecology*, 2007; vol. 14, no. 4, pp. 419–427,
- [7] Mol F, Van Mello, NM, Strandell A. Groupe de travail sur la chirurgie Européenne de la grossesse extra-utérine (ESEP). Salpingotomie versus salpingectomie chez les femmes enceintes de grossesse tubaire (étude ESEP): essai ouvert, multicentrique, contrôlé et randomisé. *Lancette.* 2014; 383: 1483-1489 [PubMed].
- [8] De Los Ríos JF, Castaneda JD, Miryam A. Bilateral ectopic pregnancy. *J Minim Invasive Gynecol* 2007; 14: 419-427.
- [9] Stabile I, Grudzinskas JG. Ectopic pregnancy: a review of incidence, etiology and diagnostic aspects. *Obstet Gynecol Surv* 1990; 45: 335-347.
- [10] Al-Quraan GA, Al-Taani MI, Nusair BM, Arafat MR, Khateeb MM. Spontaneous ruptured and intact bilateral tubal ectopic pregnancy. *East Mediterr Health J* 2007; 13: 972–974.
- [11] Bettocchi S, Nappi L, Ceci O, Vimercati A, Selvaggi L, Cormio G, Vicino M: Simultaneous bilateral tubal pregnancies and intrauterine pregnancy with five fetuses. *J Am Assoc Gynecol Laparosc* 2004, 11: 195–196.
- [12] Barnhart K T, Sammel M D, Gracia C RR. Facteurs de risque de grossesse extra-utérine chez les femmes ayant une grossesse symptomatique au premier trimestre. *Fertilité-stérilité.* 2006; 86 36-43.

- [13] Jønler M, Rasmussen KL, Lundorff P. Coexistence of bilateral tubal and intrauterine pregnancy. *Acta Obstet Gynecol Scand* 1995; 74: 750-752.
- [14] Moini A, Hosseini R, Jahangiri N, Shiva M, Akhoond MR. Risk factors for ectopic pregnancy: a case-control study. *J Res Med Sci*. 2014; 19 (9): 844–849.
- [15] Abi Khalil ED, Mufarrij SM, Moawad GN, Mufarrij IS. Spontaneous Bilateral Ectopic Pregnancy: A Case-Report. *J Reprod Med*. 2016 May-Jun; 61 (5-6): 306-8.
- [16] Creanga A. A, Shapiro-Mendoza C. K, Bish C. L. Tendence de la mortalité par grossesse extra-utérine aux USA: 1980-2007. *Obstet-Gynéco*. 2011; 117: 837-843.
- [17] Pezzani M: A case of simultaneous interstitial bilateral pregnancy. *Acta Gent Med Gemellol* 1976, 35: 325–327.
- [18] Weifeng L Gang W, Tiecheng L, Wenwen S. Misdiagnosis of bilateraltubalpregnancy: a case report. *Journal of Medical case reports* 2014; 2-3.
- [19] Fukuda T, H Inoue, Yoyama Y. Grossesses extra-utérines bilatérales tubaires et intra-uterines diagnostiquées à la laparoscopie. *Journal Gynécologie et Obstétrique*. Res 2014; 40: 2114-2117. [PubMed].